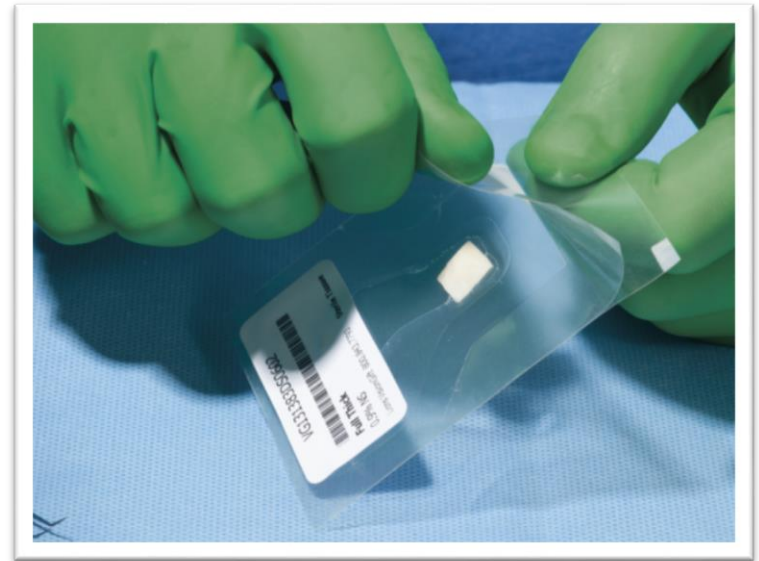


Electron beam irradiated allografts for ophthalmic surgery

ASCRS

Session - 2015 Review of New Surgical Technologies and Devices

April 21, 2015



Dr. Elena Vialova

Christopher G. Stoeger, MBA, CEBT

Disclosures

Chris Stoeger is employed by Lions VisionGift, a non-profit eye bank

Lions VisionGift has licensed some the sterilization processing technology discussed in these slides

Human tissue for ocular surgery

- Cornea
- Sclera
- Pericardium
- Others not discussed in this talk

Important Factors to Consider When Storing Tissue Long Term

Will the process used to preserve tissue affect?

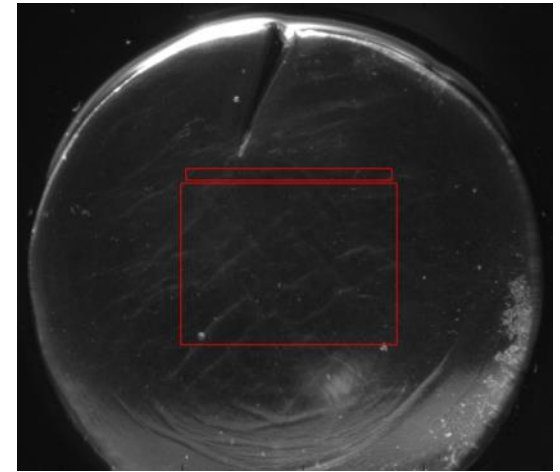
- Bioburden / Sterility/ Safety
- Tissue Handling at time of use
 - Biomechanical properties
 - Does the tissue behave as expected?
- Convenience
 - Does it require reconstitution?
 - Is it easy to deliver to the surgical field?
 - Is any special temperature required to maintain tissue integrity?
- Impact on Clarity (for Cornea)

Long-Term Storage of Cornea: e-Beam with rHSA

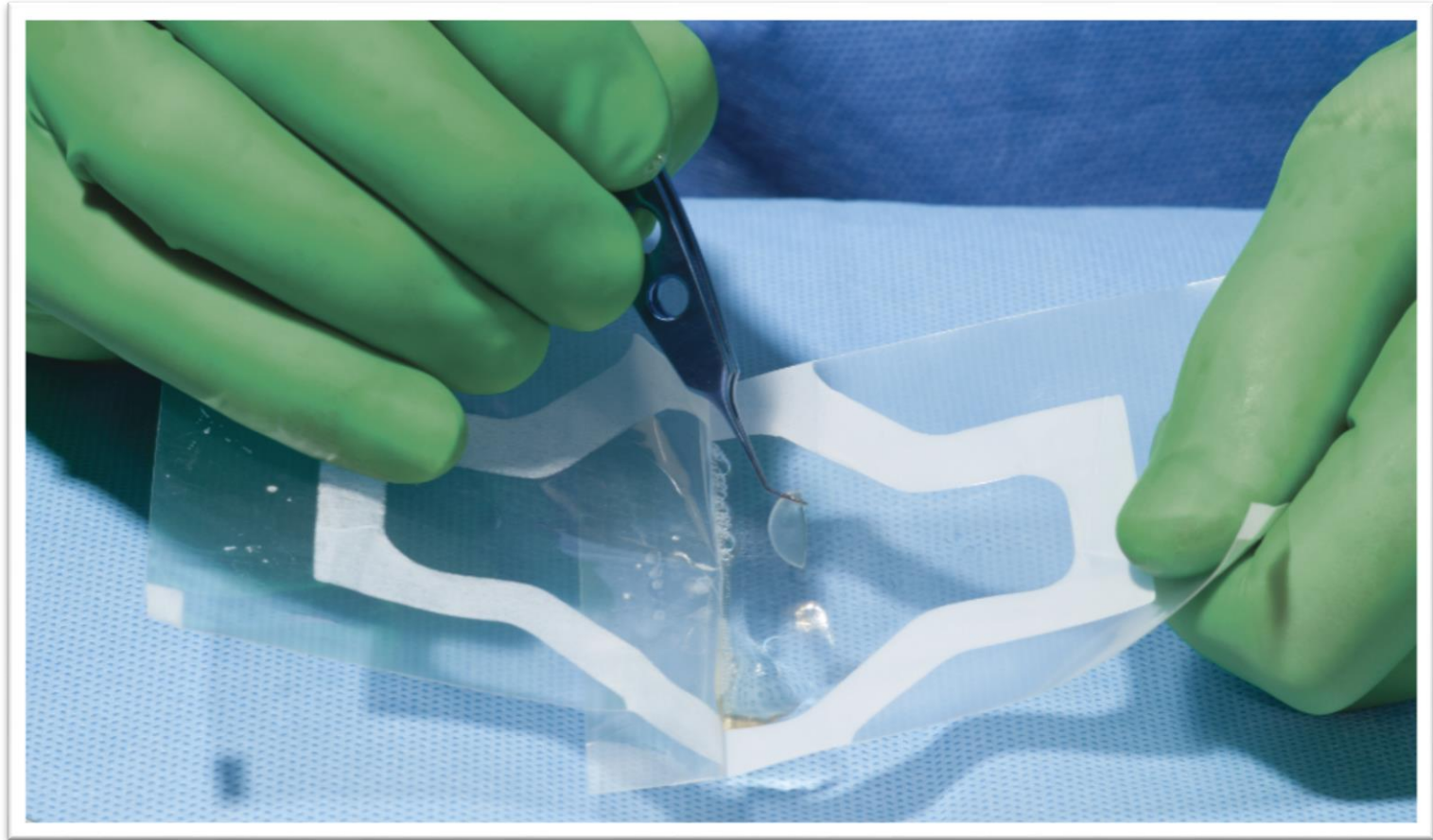
- Liquid paraffin- (1908, Carrel)
- Glycerin- (1955, King JH)
- Cryopreservation
- Irradiation: recently developed for corneas
 - Gamma Irradiation: Previously developed
 - Electron Beam Irradiation (E-Beam irradiation) : Novel Sterilization Process for corneas.

Benefits of Irradiation and rHSA

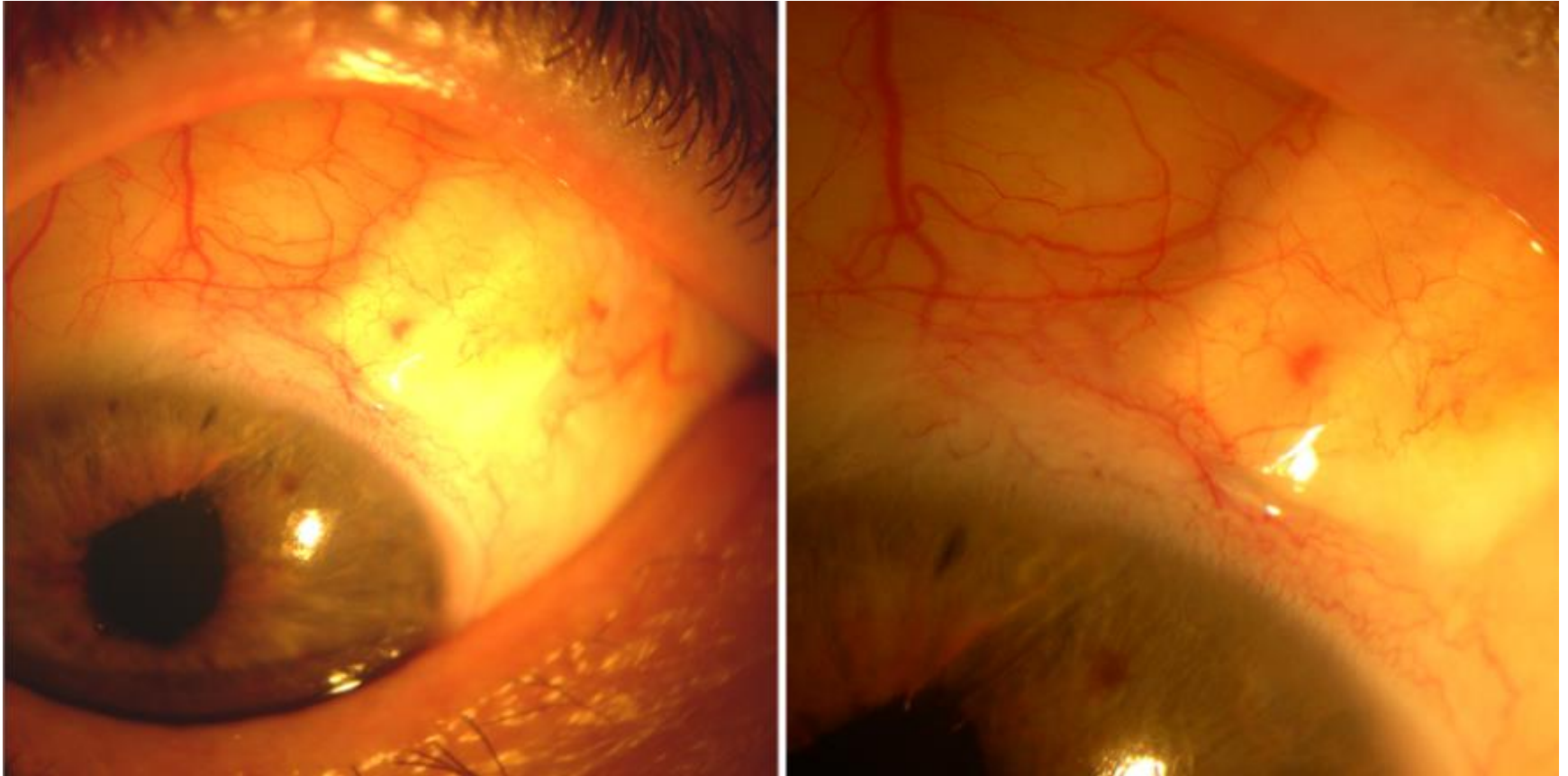
- Irradiation allows for sterilization of the graft
- The container of the tissue can be sterilized allowing for ease of use in the OR
- Electron beam irradiation is produced with electricity and does not require a radiation source such as Cobalt 60
- Recombinant albumin is an ideal storage solution as it keeps the cornea clear and contains no animal or human derived blood products.



Tissues Need to Be Easy to Use

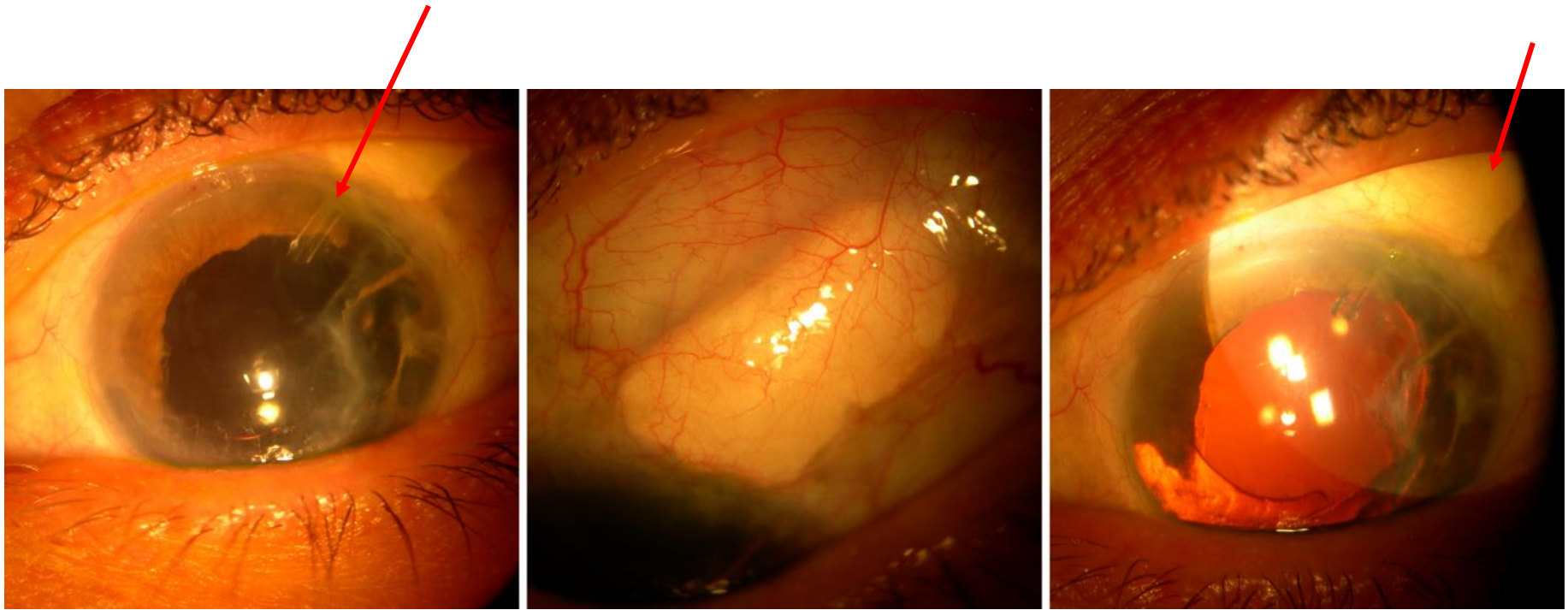


Electron Beam Irradiated Sclera for Glaucoma Tube Coverage



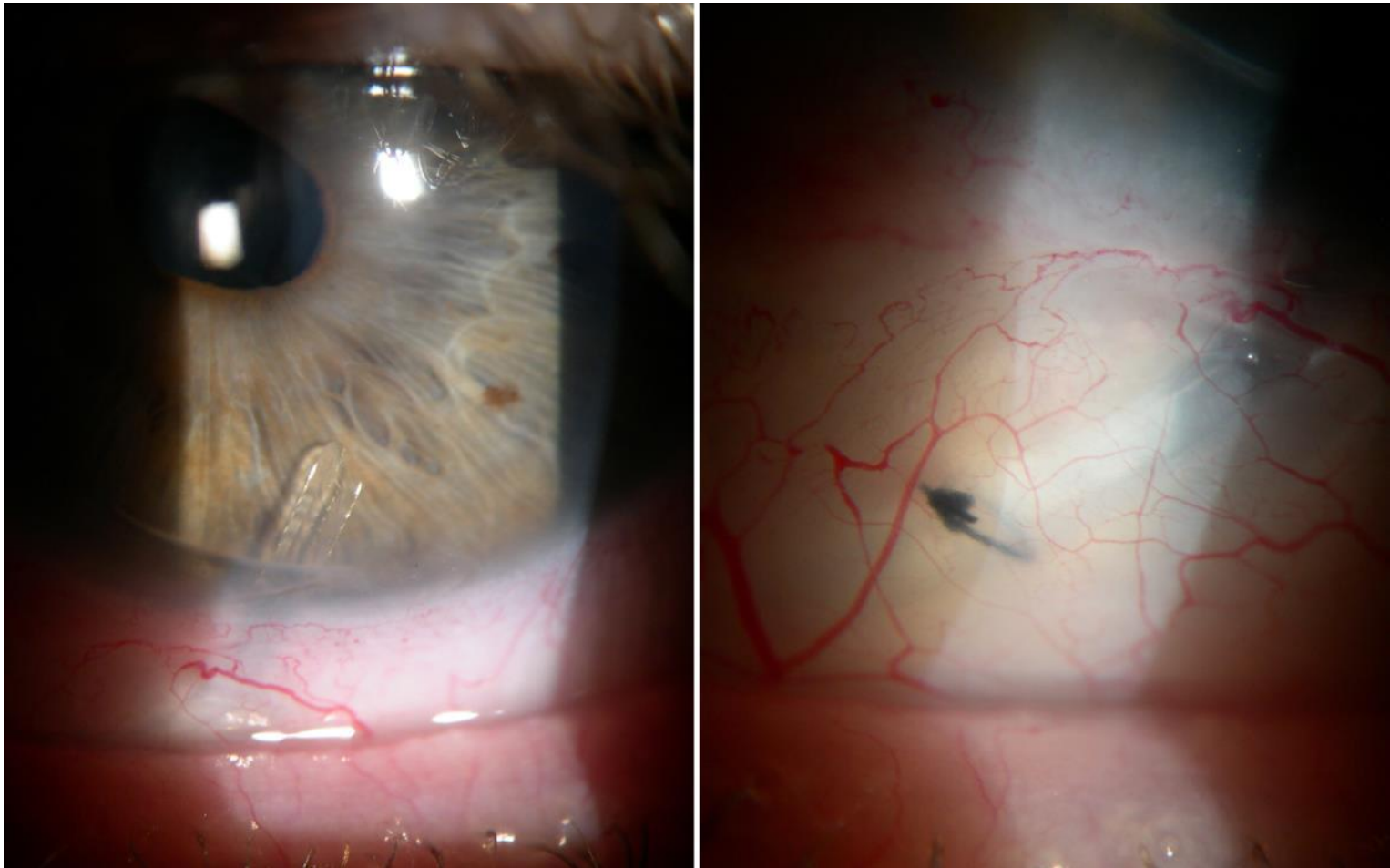
Images courtesy of Annette Sims, MD
Oregon Eye Specialists, Eugene, OR

Electron Beam Irradiated Sclera for Glaucoma Tube Coverage




Images courtesy of Annette Sims, MD
Oregon Eye Specialists, Eugene, OR

E-Beam Sterilized Cornea Graft for Inferior Tube Coverage



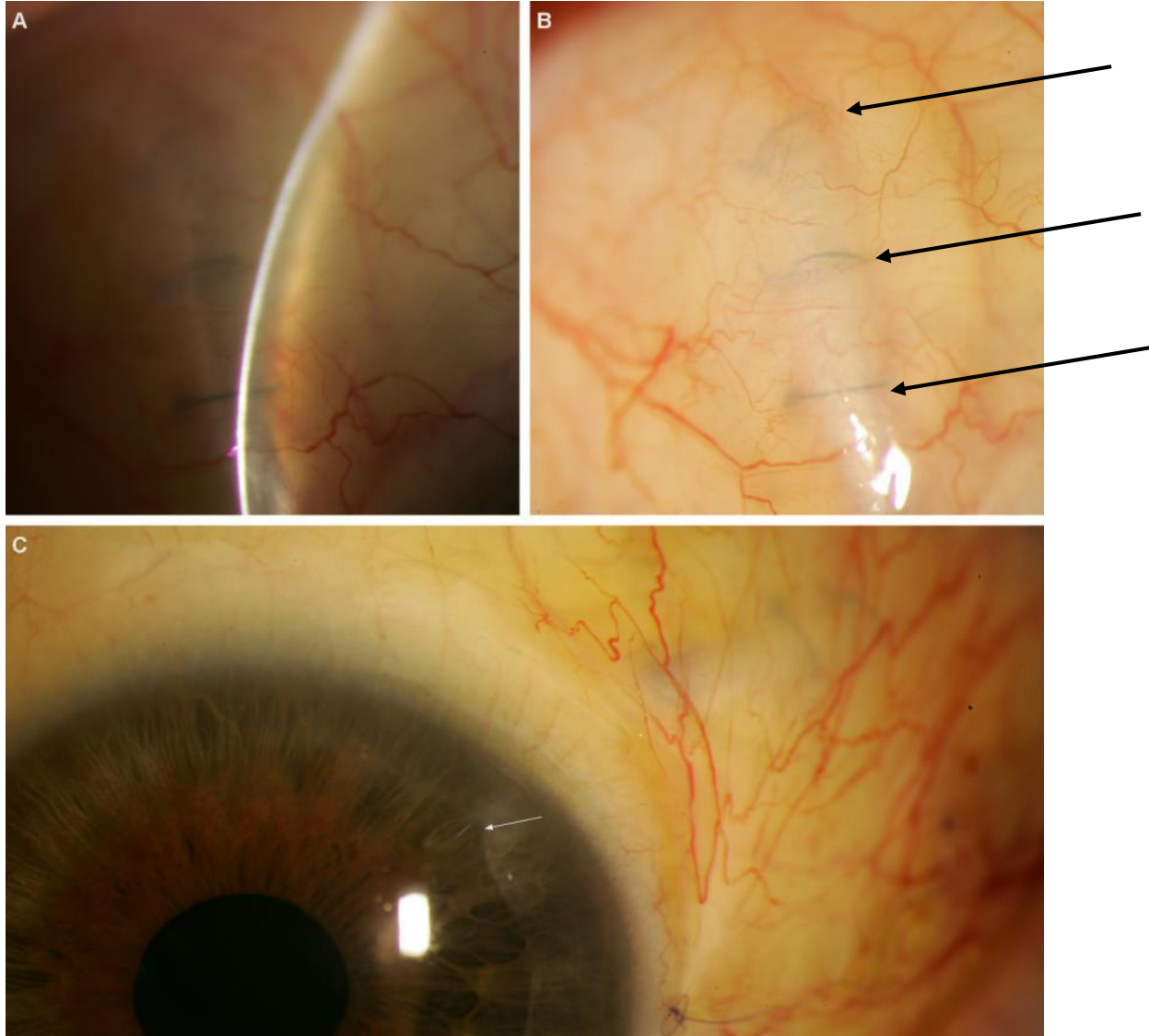
Images courtesy of Annette Sims, MD
Oregon Eye Specialists, Eugene, OR.

Electron Beam Irradidated Sclera Used for Glaucoma Shunt Coverage



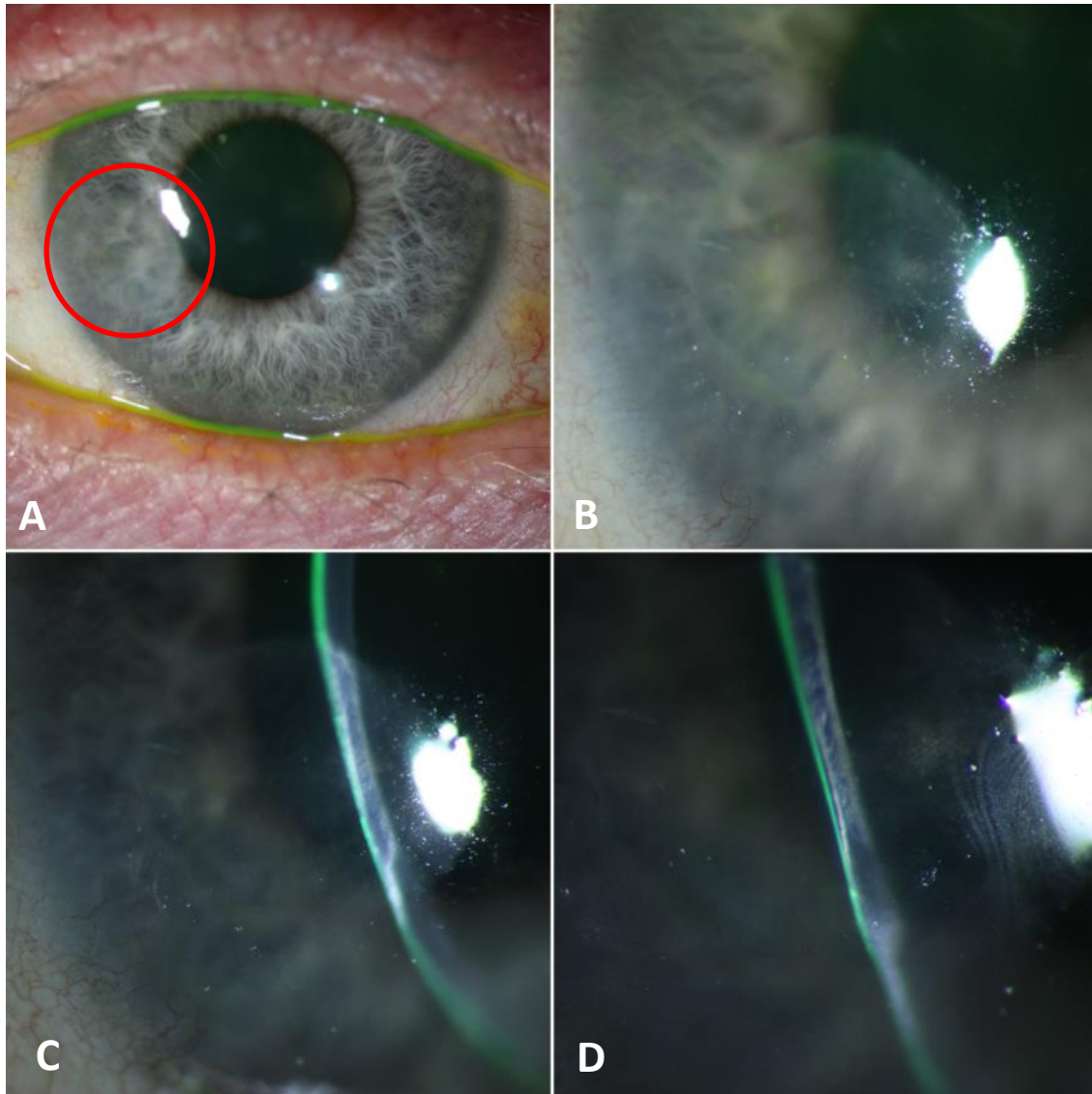
e-Beam Irradiated Cornea Used for Glaucoma Shunt

10 Weeks post-op



Photos courtesy of
Shandiz Tehrani,
MD, PhD.
Oregon Health
and Science
University

Sterile Cornea Used for Lamellar Patch

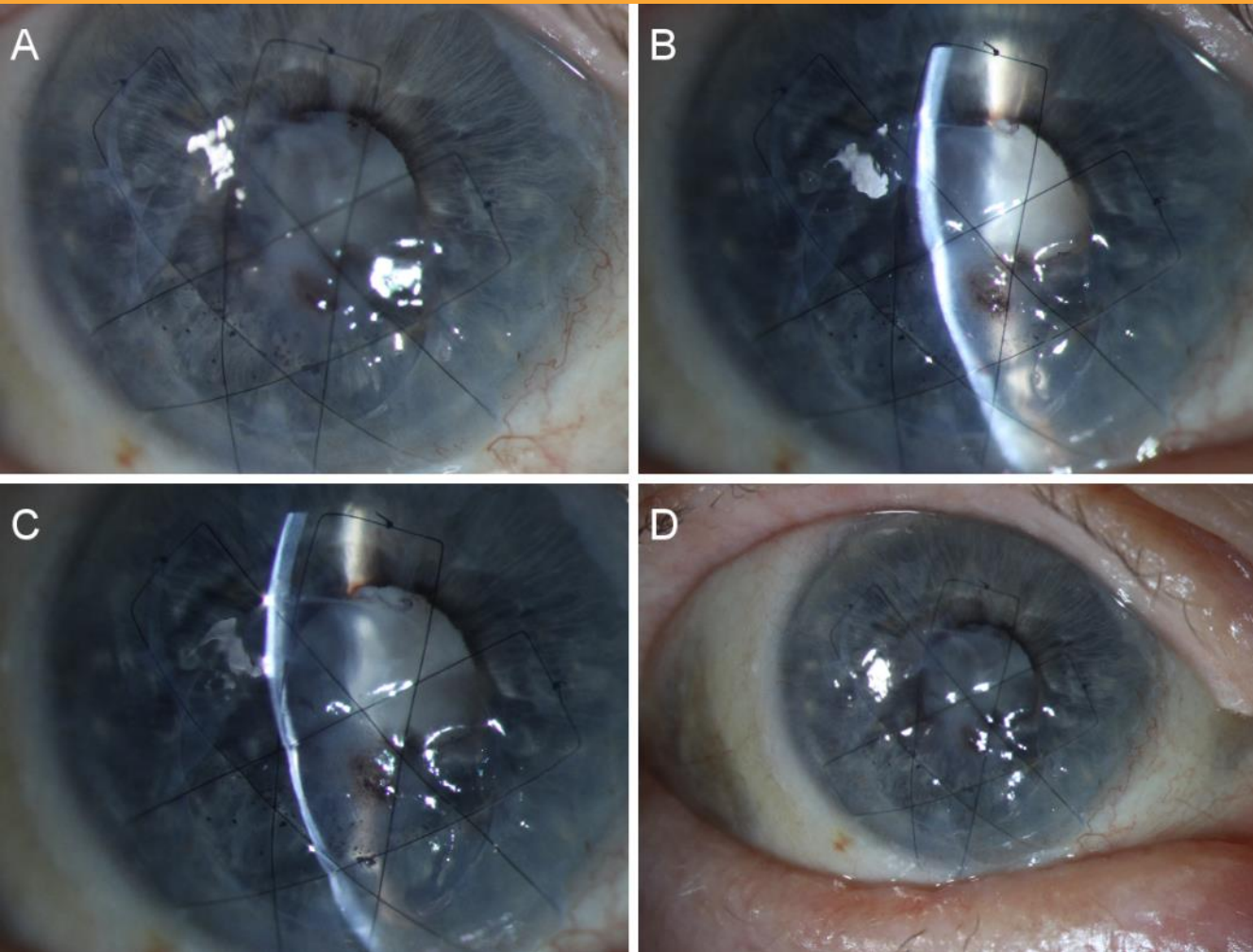


Photos courtesy of Michael Straiko, MD
Devers Eye Institute, Portland, OR

90% Corneal melt with anterior lamellar patch graft at 1 year post-op.

Patient is 50 y/o with rheumatoid arthritis. The melt continued after initial treatment with amniotic membrane. A sterile graft was secured with Tisseel glue and mattress sutures. The graft is not quite as thick as the rest of the cornea but the patient is still doing well with 20/30-20/40 vision.

Corneal Perforation Sealed with Sterile Cornea



1-2mm perforation due to *Herpes zoster* addressed with sterile lamellar cornea graft inlaid with mattress sutures and amniotic membrane.

Photos courtesy of Michael Straiko, MD
Devers Eye Institute, Portland, OR

Conclusions

- Modern tissue storage techniques provide:
 - Improved safety with irradiation and sterility assurance
 - Convenience of ambient tissue storage and peel pouches for delivery to operating field
 - Excellent clarity of corneal tissue with recombinant albumin storage medium

Thank you for your attention



Questions?

My contact information:

- chris@visiongift.org